

REVIEW

Noninvasive follicular thyroid neoplasm with papillary-like nuclear features: a problematic entity

Klaudia Zajkowska¹, Janusz Kopczyński², Stanisław Góźdz³ and Aldona Kowalska^{1,3}

¹Endocrinology, Holycross Cancer Centre, Kielce, Poland

²Surgical Pathology, Holycross Cancer Centre, Kielce, Poland

³Faculty of Health Sciences, Jan Kochanowski University, Kielce, Poland

Correspondence should be addressed to K Zajkowska: klaudia.ziemianska@gmail.com

Abstract

Noninvasive follicular thyroid neoplasm with papillary-like nuclear features (NIFTP) is a borderline thyroid tumour formerly known as noninvasive encapsulated follicular variant of papillary thyroid carcinoma. The prevalence of NIFTP is estimated at 4.4–9.1% of all papillary thyroid carcinomas worldwide; however, the rate of occurrence of NIFTP is eight times lower in Asian countries than in Western Europe and America. At the molecular level, NIFTP is characterised by the lack of *BRAF* V600E and *BRAF* V600E-like mutations or other high-risk mutations (*TERT*, *TP53*) and a high rate of *RAS* mutations, which is similar to other follicular-pattern thyroid tumours. The diagnosis of NIFTP can only be made after histological examination of the entire tumour removed during surgery and is based on strictly defined inclusion and exclusion criteria. Although the diagnosis is postoperative, the combination of certain findings of preoperative tests including ultrasonography, cytology, and molecular testing may raise suspicion of NIFTP. These tumours can be effectively treated by lobectomy, although total thyroidectomy remains an option for some patients. Radioactive iodine and thyroid stimulating hormone suppression therapy are not required. NIFTP has an extremely good prognosis, even when treated conservatively with lobectomy alone. Nevertheless, it cannot be considered as a benign lesion. The risk of adverse outcomes, including lymph node and distant metastases, is low but not negligible.

Key Words

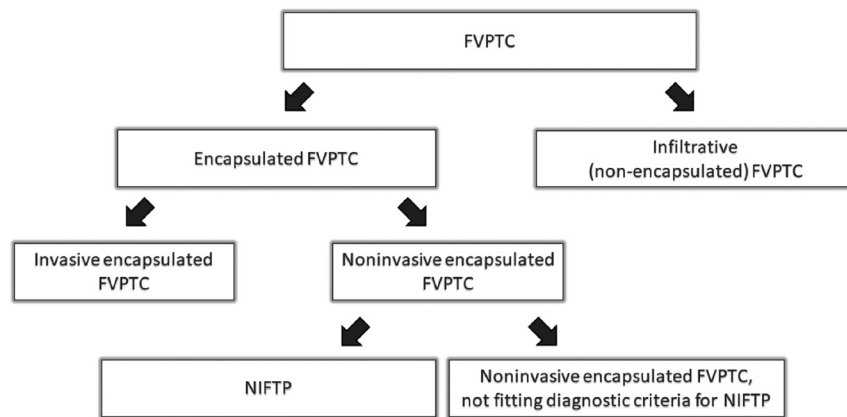
- ▶ follicular variant of PTC
- ▶ cytology
- ▶ molecular testing

Endocrine Connections
(2020) **9**, R47–R58

Introduction

The follicular variant of papillary thyroid carcinoma (FVPTC) is the second most common histological variant of papillary thyroid carcinoma (PTC) (1). There are two variants of FVPTC, non-encapsulated (infiltrative) and encapsulated. The encapsulated variant of FVPTC (EFVPTC) may exhibit features of vascular or capsular invasion (Fig. 1). Individual forms of FVPTC differ in molecular profile, clinical behaviour and prognosis (2, 3). Evidence suggests that among different variants of FVPTC, noninvasive EFVPTC has an extremely indolent clinical behaviour and good prognosis. In 2016, an international group of endocrine pathology experts led by Nikiforov

conducted a retrospective study that included 109 patients with noninvasive EFVPTC (67 patients underwent lobectomy, and none of them received radioactive iodine ablation) with a follow-up of 10–26 years and 101 patients with invasive EFVPTC observed for 1–18 years (4). In the group of patients with noninvasive EFVPTC, none died as a result of the disease, and no patients developed metastases or structural or biochemical recurrence during the follow-up period. By contrast, in the group of patients with invasive EFVPTC, adverse events were reported in 12 (12%) cases (five patients developed distant metastases to the lungs or bones, two died from the disease, one had lymph

**Figure 1**

Classification of FVPTC. FVPTC, follicular variant of papillary thyroid carcinoma; NIFTP, noninvasive follicular thyroid neoplasm with papillary-like nuclear features.

node recurrence, one had persistent disease and five had detectable serum thyroglobulin (Tg) concentration) (4). On the basis of the obtained results and literature review, the authors proposed that the name ‘noninvasive encapsulated FVPTC’ be replaced with the term ‘noninvasive follicular thyroid neoplasm with papillary-like nuclear features (NIFTP)’ to emphasise the indolent course of the disease and to eliminate the word ‘carcinoma’ and thus its clinical and psychological consequences (4). The term NIFTP was adopted by the scientific community (5, 6) and included in the latest edition of the World Health Organization (WHO) Classification of Tumours of Endocrine Organs in the group ‘follicular patterned neoplasms with borderline clinical behaviour’, along with follicular tumour of uncertain malignant potential (FT-UMP) and well differentiated tumour of uncertain malignant potential (WDT-UMP) (7).

Although more than 3 years have passed since the introduction of the term NIFTP, there are still controversies concerning the criteria for the diagnosis of NIFTP based on postoperative examination, the potential for preoperative differentiation of NIFTP from other variants of FVPTC and the clinical behaviour, treatment and monitoring of patients with NIFTP.

Epidemiology

When Nikiforov *et al.* proposed the reclassification of noninvasive EFVPTC as NIFTP, they estimated that the new diagnosis would affect more than 45,000 patients worldwide each year (4). The predictions, which were based on retrospective data from four institutions (three Italian and one American), resulted in a calculated rate of NIFTP of 18.6% among all PTC cases (4). After more than 3 years from the introduction of the new nomenclature, it appears that the initial calculations were overestimated (8, 9, 10, 11, 12, 13, 14, 15, 16, 17, 18, 19, 20, 21).

According to the meta-analysis conducted by Bychkov *et al.* (25 studies, 46,948 patients with PTC), the prevalence of NIFTP is 9.1% (95% CI, 6.0–12.7%) of all PTC cases; the rate of NIFTP is considerably lower in the Asian population (1.6%, 95% CI, 0.9–2.5%) than in Western Europe and America (13.3%, 95% CI, 9.0–18.3%) (22). The observed difference in NIFTP prevalence between Asian and non-Asian countries can be attributed to ethnic variance (different mutation profiles of thyroid cancer) (23), differences in the interpretation of histological criteria (24) and differences in clinical practice (lower resection rates in patients with indeterminate thyroid cytologies) (25). Prevalence of NIFTP in PTC in selected Western European and American studies compared to Asian studies is presented in Table 1.

Large differences in the incidence of NIFTP have been reported not only between countries but also between different institutions in the same country (USA, 4.0–27.0%; Korea, 1.3–2.7%), which, at least in part, may be attributable to different study designs (retrospective/prospective), sources of data collection (via cytologic/surgical pathology database) and the inclusion or exclusion of microcarcinomas from NIFTP.

The latest meta-analysis conducted by Ruanpeng *et al.* (11 studies, 27,866 patients with PTC) indicated that the prevalence of NIFTP among PTC is 4.4% (95% CI, 2.0–9.0%) (26), which is definitely lower than that reported by Bychkov. Such a difference may be surprising because both meta-analyses were partially based on the same studies (22, 26). The reason for this difference may be that the study by Ruanpeng enrolled more patients from Asian countries (in which the prevalence of NIFTP is several times lower than in non-Asian populations): the proportion of Asian patients in the study by Bychkov was 63.7% (29,896 out of 46,948 patients with PTC), whereas that in the study by Ruanpeng was 77.8% (21,667 out of 27,866).

Table 1 Prevalence of NIFTP in PTC in selected Western European and American studies compared to Asian studies.

Geographical region	Source	Country	Total	NIFTP %
Western Europe and America	Jaconi <i>et al.</i> (8)	Italy	14/51	27.5
	Kopczyński <i>et al.</i> (9)	Poland	12/214	5.6
	Canberk <i>et al.</i> (10)	Portugal	74/3466	2.1
	Li <i>et al.</i> (11)	USA	17/252	6.7
	Mao <i>et al.</i> (12)	USA	32/454	7.0
	Point du Jour <i>et al.</i> (13)	USA	17/420	4.0
	Wong <i>et al.</i> (14)	USA	94/348	27.0
	Parente <i>et al.</i> (15)	Canada	102/4790	2.1
	Eskander <i>et al.</i> (16) ^a	Canada	318/2846	11.2
	Asia	Hirokawa <i>et al.</i> (17)	Japan	54/10,076
Kim <i>et al.</i> (18)		Korea	73/2853	2.5
Lee <i>et al.</i> (19)		Korea	21/769	2.7
Cho <i>et al.</i> (20)		Korea	95/6269	1.5
Seo <i>et al.</i> (21) ^b		Korea	238/18,819	1.3

^aCalculations based on pathological reports. ^bData collected from eight institutions in Korea.

NIFTP, noninvasive follicular thyroid neoplasm with papillary-like nuclear features; PTC, papillary thyroid carcinoma.

Molecular pathogenesis of NIFTP

At the molecular level, NIFTP is characterised by the lack of *BRAF* V600E and *BRAF* V600E-like mutations or other high-risk mutations and a high rate of *RAS* mutations. This is similar to follicular-pattern thyroid tumours, including follicular adenoma (FA), follicular thyroid carcinoma (FTC) and FVPTC (4, 27, 28, 29, 30). It is suggested that NIFTP represents an anticipated precursor of invasive EFVPTC (4, 31). Activating mutations of the *RAS* gene are detected in 30–67% of NIFTP cases; the most common mutation affects *NRAS*, followed by *HRAS* and *KRAS* genes (4, 27, 28, 29, 30, 32, 33). Other less common genetic alterations found in NIFTP include *PPARG* fusions (4, 27, 33), *THADA* fusions (4, 27) and *BRAF* K600E mutations (4, 28, 31, 32). Rarely, tumours harbouring high-risk mutations such as *TERT* promoter mutations and *ETV6-NTRK3* fusions may have a morphology that overlaps with NIFTP (30, 34). However, the presence of any high-risk mutations constitutes the exclusion criterion for NIFTP diagnosis and should trigger an exhaustive search for morphologic exclusion criteria (35).

Evolution of the diagnostic criteria of NIFTP

The diagnosis of NIFTP can only be made after histological examination of the entire tumour removed during surgery and is based on strictly defined inclusion and exclusion criteria (4, 35). According to the original criteria, histological examination NIFTP should show an encapsulated or clearly demarcated nodule, with cells exhibiting a follicular growth pattern and nuclei

typical of PTC. NIFTP should not display any features of vascular or capsular invasion, tumour necrosis, high mitotic activity (defined as three or more mitoses per ten high-power fields ($\times 40$)), papillae >1%, psammoma bodies or morphologic characteristics of other variants of PTC, such as tall cell, cribriform-morular and solid/trabecular variants (4).

The absence of capsular and vascular invasion is critical to the diagnosis of NIFTP (4). To ensure this issue, the entire tumour capsule or tumour normal interface should be submitted for histological examination (36). For large lesions, stepwise submission of sections (with an initial generous but limited sampling, followed by submission of the remainder of the tumoral capsule if no vascular or capsular invasion is initially detected) is acceptable (36). However, there is no clear recommendation on how to evaluate effectively the entire tumour capsule. A recently published study by Oh *et al.* presented a modified transverse-vertical gross examination method with additional vertical cuts at the upper and lower ends of thyroid nodules (37). This modified transverse-vertical gross examination method was more effective than the conventional transverse examination method for the detection of capsular invasion and might allow a better differential diagnosis between NIFTP and invasive EFVPTC (37).

It should be noted that not all cases previously diagnosed as noninvasive EFVPTC meet the exact definition of NIFTP, which is more rigorous (13) (Fig. 1).

The introduction of the term NIFTP led to a discussion on the diagnostic criteria used. Particularly questionable was the presence of papillary structures associated with the occurrence of *BRAF* V600E mutations and regional lymph node metastases (18, 20, 38). These features (the presence of papillae, *BRAF* V600E mutations and lymph node

metastases) are characteristic of classic PTC (cPTC) rather than FVPTC, which raises concerns that the incorrect application of diagnostic criteria for NIFTP can lead to misdiagnosis of cPTC with a prominent follicular pattern as NIFTP (35). As a result, revised diagnostic criteria for NIFTP have been proposed (35). The criterion ‘less than 1% papillae’ was changed to ‘no well-formed papillae’. In cases showing pronounced nuclear features of PTC (nuclear score 3), the entire tumour should be examined to exclude the presence of papillary structures. In addition, secondary criteria (molecular testing for *BRAF* V600E and other high-risk mutations and immunohistochemistry for *BRAF* V600E) were added that may be helpful but are not required for the diagnosis of NIFTP (35). A summary of the initial and revised NIFTP diagnostic criteria is presented in Table 2. The change of diagnostic criteria for NIFTP has reduced the number of NIFTP diagnoses (20).

Another controversy over diagnostic criteria of NIFTP concerns the size of the tumour and multifocality. According to the original study by Nikiforov *et al.*, neither tumour size nor multifocality were included to establish the diagnosis criteria of NIFTP (4). However, the study did not include subcentimeter, large (≥ 4 cm) and multifocal tumours, which raises doubts as to whether such tumours can be classified as NIFTPs.

The recommendations specify that the diagnosis of NIFTP should not be based on retrospective interpretation of pathologic reports (6, 39).

Clinical and ultrasonographic features

In clinical practice, NIFTP presents as a single nodule (10) or a lesion in the context of a multinodular background (27, 40, 41). The multifocal form of NIFTP is present in

2.7–14.7% of patients (10, 40, 42). The coexistence of a malignant lesion in the same or in the second lobe of the thyroid may affect 14.9–46.3% of NIFTP patients (it most often coexists with papillary thyroid microcarcinoma) (10, 21, 41).

On ultrasound (US) examination, NIFTP is usually a well-circumscribed, oval-to-round nodule with regular margins and variable echogenicity, ranging from markedly hypoechoic to hypoechoic, isoechoic and heterogeneous (27, 41, 43, 44, 45). Such significant differences in the reported echogenicity of NIFTPs are not surprising because echogenicity is considered to be the feature with the lowest inter-observer agreement (46, 47, 48). The presence of calcifications is rare (27, 41, 44). On Power Doppler US, NIFTPs are mostly hypervascular (45, 49), and usually present a mixed (peripheral and intranodular) type of vascularisation (49).

On US, NIFTP corresponds to a lesion with a low or intermediate suspicion pattern according to the ultrasonographic classification of the American Thyroid Association (ATA) (44, 50, 51). Similarly, according to the Thyroid Imaging Reporting and Data System (TI-RADS) proposed by the American College of Radiology (ACR), nodules consistent with NIFTP are mostly qualified as TR3 (mildly suspicious) and TR4 (moderately suspicious) (52). The exclusion of NIFTPs from malignant tumours decreases the risk of malignancy (ROM) of the ATA and TI-RADS categories to a degree dependent on the pre-test probability and prevalence of NIFTP in the studied population (52, 53).

NIFTP in fine-needle aspiration biopsy

NIFTP is a postoperative diagnosis and cannot be diagnosed solely on the basis of fine-needle aspiration

Table 2 Initial and revised diagnostic criteria for NIFTP according to Nikiforov *et al.* (4, 35).

Initial diagnostic criteria for NIFTP	Revised diagnostic criteria for NIFTP	
	Primary	Secondary ^a
Encapsulation or clear demarcation	Encapsulation or clear demarcation	Lack of <i>BRAF</i> V600E mutation detected by molecular assays or immunohistochemistry
Follicular growth pattern with: <ul style="list-style-type: none"> <1% papillae No psammoma bodies <30% solid/trabecular/insular growth pattern 	Follicular growth pattern with: <ul style="list-style-type: none"> No well-formed papillae No psammoma bodies <30% solid/trabecular/insular growth pattern 	Lack of <i>BRAF</i> V600E-like mutations or other high-risk mutations (<i>TERT</i> , <i>TP53</i>)
Nuclear score, 2–3	Nuclear score, 2–3	
No vascular or capsular invasion	No vascular or capsular invasion	
No tumour necrosis	No tumour necrosis	
No high mitotic activity	No high mitotic activity	

^aSecondary criteria are helpful but not required for NIFTP diagnosis. NIFTP, noninvasive follicular thyroid neoplasm with papillary-like nuclear features.

biopsy (FNAB); however, certain cytological features may raise suspicion of NIFTP (54, 55). FNAB samples usually show scant colloid with abundant small clusters of follicular cells and microfollicles and nuclear atypia including enlarged, oval-shaped nuclei, nuclear grooves, chromatin clearing, rare nuclear pseudo-inclusions and no true papillae (56, 57, 58).

In preoperative cytology, NIFTP can belong to any of the six categories of the Bethesda System for Reporting Thyroid Cytopathology (TBSRTC), although it is most often found in so-called ‘indeterminate’ categories (59). A meta-analysis carried out by Bongiovanni *et al.*, which included 15 studies and 915 histologically confirmed cases of NIFTP with corresponding cytology, indicated the following distribution of NIFTP in the TBSRTC categories: nondiagnostic, 3%; benign, 10%; atypia of undetermined significance or follicular lesion of undetermined significance (AUS/FLUS), 30%; follicular neoplasm or suspicious for a follicular neoplasm (FN/SFN), 21%; suspicious for malignancy (SM), 24% and malignant, 8% (59).

Recently updated Bethesda classification recommends subclassification of the AUS/FLUS category (54). When considering AUS/FLUS subcategories, NIFTP is most often classified as architectural atypia (AUS-A) or cytologic and architectural atypia (AUS-C&A) (60). It is not surprising, since NIFTP smears are characterised by the presence of microfollicles. Subcategories can help in the prediction of the type of neoplasia (60). AUS-A and AUS-C&A subcategories can rise the suspicion of NIFTP and help in selection of appropriate molecular tests.

To raise the clinicians’ awareness of the fact that NIFTP constitutes a substantial proportion of the ‘malignancies’ hidden in TBSRTC categories, optional education notes suggesting a diagnosis of NIFTP may be used by cytopathologists (27).

The reclassification of NIFTP as a non-malignant lesion decreases the ROM in most Bethesda categories; the scale of the impact differs significantly among various institutions (9, 11, 61, 62, 63, 64, 65, 66, 67, 68, 69, 70). According to the latest large meta-analysis conducted by Vuong *et al.* (14 studies, 14,153 resected nodules), the highest absolute decrease in ROM was observed in SM, FN/SFN and AUS/FLUS categories (15.8%, 10.6% and 9.5%, respectively) (71). The ROM changes in particular Bethesda categories are significantly lower in Asian than in Western countries (71, 72), which is attributed to a lower prevalence of NIFTP in the Asian population. Another meta-analysis assessing the impact of NIFTP on the ROM in patients undergoing surgery for SM or malignant FNAB findings shows that the inclusion of NIFTP leads to a reduction in the ROM for SM and malignant diagnostic categories by 14% and 3%, respectively (73). A comparison of the results of both meta-analyses with the data reported by Cibas *et al.* (54) is presented in Table 3. All the studies included in these meta-analyses used the diagnostic criteria for NIFTP proposed initially by Nikiforov in 2016. Further studies evaluating the impact of NIFTP on ROM should be conducted using the revised criteria.

Attempts at preoperative identification of NIFTP

Since NIFTP is considered a non-malignant lesion and requires a different management than carcinoma, including a different scope of surgical treatment, it would be highly useful to preoperatively differentiate NIFTP from non-NIFTP lesions.

Several studies have shown that NIFTP can be differentiated from cPTC in cytological examination based

Table 3 ROM changes in Bethesda categories after reclassification of NIFTP according to Vuong *et al.* (71) and Bongiovanni *et al.* (73) in comparison with data reported by Cibas *et al.* (54).

Diagnostic category	Data reported by Cibas <i>et al.</i>			Vuong <i>et al.</i>	Bongiovanni <i>et al.</i>
	ROM if NIFTP = CA (%)	ROM if NIFTP ≠ CA (%)	Absolute ROM decrease (%)	Absolute ROM decrease (%)	Absolute ROM decrease (%)
ND	5–10	5–10	0	2.2	–
Benign	0–3	0–3	0	1.6	–
AUS/FLUS	10–30	6–18	4–12	9.5	–
FN/SFN	25–40	10–40	0–15	10.6	–
SM	50–75	45–60	5–15	15.8	14
Malignant	97–99	94–96	3	2.3	3

AUS/FLUS, atypia of undetermined significance or follicular lesion of undetermined significance; CA, carcinoma; FN/SFN, follicular neoplasm or suspicious for follicular neoplasm; ND, nondiagnostic; NIFTP, noninvasive follicular thyroid neoplasm with papillary-like nuclear features; ROM, risk of malignancy; SM, suspicious for malignancy.

on a combination of certain features, such as the presence of true papillae, pseudo-inclusions, psammomatous calcifications, multinucleate giant cells and follicular architecture (57, 74, 75, 76). Moreover, NIFTP and cPTC have different molecular profiles: NIFTP is characterised by the frequent occurrence of *RAS* mutations and the lack of *BRAF* V600E mutations, whereas these are often encountered in cPTC (4, 77). Similarly, the cytological features make it possible to differentiate NIFTP from most benign lesions including FAs (57, 58, 78, 79). The most demanding task is to preoperatively differentiate NIFTP from other FVPTCs.

Certain ultrasound features may be helpful for distinguishing NIFTP from infiltrative FVPTC (IFVPTC) (51, 80, 81). NIFTP most commonly presents as a round-to-oval nodule with smooth margins, whereas IFVPTC is characterised by an irregular shape and spiculated margins, which are associated with the infiltrative growth of this tumour (51). Consequently, a high-suspicion pattern on US is significantly more frequent in IFVPTC than in NIFTP (51, 82). However, studies suggest that ultrasonography is insufficient for differentiating NIFTP from invasive EFVPTC (80, 81, 83). Both tumours show a similar appearance in cytological examinations as well (58, 76, 80, 83, 84). This is not surprising given that NIFTP can be differentiated from invasive EFVPTC by the exclusion of capsular and vascular invasion based on histological examination of the entire tumour along with the capsule (4, 35).

The molecular profile of these tumours may prove helpful for the preoperative differentiation of NIFTP from invasive EFVPTC. Although *RAS* mutations occur in both tumour types with similar frequency (29, 30, 85), *BRAF* V600E and *TERT* promoter mutations are not found in NIFTP, whereas they may be present in a small percentage of invasive EFVPTC (29, 83, 85, 86, 87).

Because NIFTP is most commonly found among indeterminate categories in preoperative cytology, some NIFTP patients are diagnosed using commercially available molecular tests. The most widely used tests, Afirma Gene Expression Classifier (Afirma GEC) and ThyroSeq, were developed to reduce the number of thyroidectomies in patients with indeterminate nodules. Most cases of NIFTP are classified as 'suspicious' in GEC (27, 32, 34, 41, 88) and 'positive results' in ThyroSeq tests ('HR mutation group' in ThyroSeq v2 and 'RAS-like-group' in ThyroSeq v3) (27, 32, 34, 88, 89, 90).

To sum up, the existence of overlapping features between NIFTP and invasive EFVPTC is evident. A diagnosis of NIFTP may be suggested but cannot be certain until a full histological examination of the material obtained

during surgery has been performed. A low or intermediate suspicion pattern on US combined with indeterminate cytology and a 'suspicious' result of GEC/presence of *RAS* mutation in ThyroSeq should raise suspicion of NIFTP and lead the clinician to consider less aggressive treatment options.

Doubts concerning the indolent behaviour of NIFTP

According to Nikiforov's original study, NIFTP has an indolent behaviour and an extremely good prognosis (4). Since the introduction of the term NIFTP, many studies have confirmed the low risk of adverse outcomes, including in multifocal, large and small tumours (≥ 4 and ≤ 1 cm, respectively).

A study by Rosario *et al.* (50) included 129 patients with NIFTP >1 cm, of whom 65 underwent lobectomy and 64 underwent total thyroidectomy, with no patients treated with radioiodine. During a follow-up of 12–146 months (median, 72 months) after surgery, none of the patients developed structural disease, and the concentrations of Tg and anti-Tg antibodies were stable in all patients (50).

In another study, 94 cases of EFVPTC (77 noninvasive FVPTC and 17 invasive FVPTC), including multifocal ($n=20$) and bilateral ($n=13$) tumours ranging in size from 0.7 to 9.5 cm (mean, 3.3 cm), were observed for 1.2–12.5 years (median, 11.8 years) after treatment (lobectomy alone in 41, thyroidectomy alone in 34, completion thyroidectomy in 19 and combination with postoperative radioactive iodine ablation in 25 patients); there was no evidence of recurrence based on biochemical or structural disease (42). The outcomes were identical regardless of the presence of capsular and lymphovascular invasion (42).

A recently published multi-institutional Korean study identified 238 cases of NIFTP, including 152 tumours with a diameter ≥ 1 cm (35% of patients underwent total thyroidectomy, 65% underwent lobectomy or isthmectomy and another 23% received radioiodine remnant ablation therapy). The mean follow-up was 37.7 months, and no patient with NIFTP had evidence of lymph node, or distant metastasis or disease recurrence during the follow-up period (21).

These and many other studies, including those with a smaller number of cases, confirm that the application of strict criteria for the diagnosis of NIFTP means that metastasis and *BRAF* mutations are not observed (13, 91, 92). Moreover, the available data indicate that both large NIFTPs (with a diameter ≥ 4 cm) and tumours with

a diameter ≤ 1 cm that meet the NIFTP criteria (not included in the original study because of limited or lack of supportive data) do not differ from their 'average size' counterparts and show exceptionally indolent behaviour (93, 94, 95, 96).

Although most publications confirm the favourable course of NIFTP, there are a few reports suggesting that lesions diagnosed as NIFTP can be associated with metastases.

A study by Cho *et al.* (20) examined the frequency of lymph node metastasis in a cohort of 154 patients with EFVPTC. When the cut-off of 1% papillae was used, the rate of lymph node metastasis was 3% and the rate of *BRAF* V600E mutation was 10% in noninvasive tumours. When the absence of a papillary structure was applied as a rigid diagnostic criterion, no *BRAF* V600E mutation was found in any of the tumours. However, central lymph node micrometastases still occurred in 3% of noninvasive tumours despite the absence of papillae and *BRAF* V600E mutations (20). It should be emphasised that prophylactic central neck dissection was performed in the study, which might have increased the incidence of clinically significant lymph node metastases.

A study by Parente *et al.* (15) found that the rate of adverse oncologic events was 6% (6/102) in patients with NIFTP; these included metastases to regional lymph nodes in five patients and distant metastases (to lungs) in one patient. The study did not include routine central neck dissection in the absence of preoperatively suspicious lymph nodes. Moreover, tumours with any true papillae were excluded, but no molecular tests were performed, especially for *BRAF* V600E mutations (15).

Another study (38) reported 3/43 noninvasive EFVPTC cases with lymph node metastases. However, the metastases originated from noninvasive EFVPTC in only one case, whereas in the other cases, they were derived from coexisting conventional PTCs. The only noninvasive EFVPTC tumour with metastases tested negative for *BRAF* V600E mutation and lacked well-formed papillae (38).

Finally, a recent controversial study conducted by Canadian researchers led by Eskander (16), which included 318 patients with NIFTP diagnosed based on pathological reports, indicated that during a median follow-up of 15.3 years, disease failure (defined as death from thyroid cancer or a recurrence event) occurred in 30 patients (9.4%) (16). The main limitation of the study was that it based the diagnosis of NIFTP on a thorough review of pathology reports, without at least reviewing the slides, which is inconsistent with current recommendations (6, 39). Moreover, as the authors themselves state,

the quality of the reports was poor or very poor in 50% of cases. In particular, the availability of information on the presence of features such as true papillae, psammoma bodies, infiltrative borders, tumour necrosis, high mitotic rate and morphologic features of an aggressive variant were 'unstated' in 87%, 74%, 89%, 95%, 90% and 90% of cases, respectively (16). These limitations give rise to a reasonable suspicion that at least some of the tumours considered as NIFTP were in fact carcinomas.

To conclude, some of the described cases of adverse outcomes of NIFTP could be related to a misdiagnosis; the exclusion of the *BRAF* V600E mutation in Parente's study, as well as basing the diagnosis of NIFTP on slides review rather than on pathology reports in Eskander's study, might have resulted in a change of diagnosis to malignancy. However, some of the cases described previously do indeed appear to be NIFTPs.

Taken together, the available data indicate that NIFTP diagnosed according to strict inclusion and exclusion criteria has an extremely indolent clinical behaviour, even when treated conservatively with lobectomy and without radioactive iodine therapy. Nevertheless, it cannot be considered as a benign lesion. The risk of adverse outcomes, including metastases, is very low but not negligible.

Treatment and monitoring

According to the ATA Thyroid Nodules and Differentiated Thyroid Cancer Guidelines, patients with tumours diagnosed as NIFTP are subject to the same recommendations as patients with low risk for recurrence differentiated thyroid carcinoma, namely, lobectomy is sufficient, remnant ablation is not recommended and thyrotropin target levels should be kept between 0.5 and 2 mIU/L (5).

However, since the definitive diagnosis of NIFTP can only be made based on postoperative histological examination, total thyroidectomy remains an acceptable option for some cases of NIFTP. This was emphasised in the recommendations of the American Head and Neck Society Endocrine Section Consensus Statement (39). The decision on the extent of surgical treatment (lobectomy vs total thyroidectomy) should be made on the basis of physical examination, ultrasound data and molecular and patient/endocrine characteristics. In particular, the patient should be informed of the potential need for a second surgery and should be ready to undergo such a surgery when lobectomy is considered (39).

Decisions on the extent of surgery should consider that bilateral disease and multifocal disease are part of the

spectrum of NIFTP neoplasms (10, 40, 42). The coexistence of malignant lesions in the same or the other thyroid lobe may affect up to 15–46% of NIFTP patients (10, 21, 41). In the study by Canberk *et al.*, 15% of NIFTP cases (11/74) were accompanied by malignant lesions in the contralateral thyroid lobe, including five PTCs, five microcarcinoma FVPTCs and one IFVPTC; two of the contralateral malignancies showed microscopic extrathyroidal extension (10). When deciding on lobectomy, the contralateral lobe must be assessed with special caution to prevent missing the coexistence of a malignant lesion.

There are currently no recommendations regarding the monitoring of patients with NIFTP. The ATA Thyroid Nodules and Differentiated Thyroid Cancer Guidelines Task Force suggest that ‘occasional monitoring with serum Tg and neck ultrasound can be considered, depending upon patient’s context, but this is not mandatory’ (5). Some authors suggest that after complete resection of NIFTP, negative postoperative assessment (defined by a Tg concentration ≤ 2 ng/mL in patients undergoing total thyroidectomy and ≤ 10 ng/mL in those undergoing lobectomy, in the absence of anti-Tg antibodies and neck ultrasonography without abnormalities) can be used to exclude the need for long-term repetition of these tests (97).

However, in the light of recent reports of a possible adverse outcome of NIFTP (15, 16, 20, 38), monitoring of these patients seems reasonable. The frequency and length of monitoring of NIFTP patients should be considered individually depending on the presence of risk factors (a surgical history of lobectomy/thyroidectomy, the presence of thyroid nodules in the remaining lobe or the results of postoperative assessment).

Conclusions and perspectives

Three years after its introduction into clinical practice, the diagnosis of NIFTP still poses a challenge for clinicians, ultrasonographers and cytopathologists. Although the diagnosis is postoperative, accurate preoperative assessment may raise suspicion of NIFTP and indicate a more conservative management. Positive results in the GEC and ThyroSeq molecular tests may be associated with NIFTP and should therefore be interpreted in the context of ultrasonographic and cytological features.

Although lobectomy is sufficient for the treatment of NIFTP, total thyroidectomy remains an option for some patients, particularly for those who do not accept the need for monitoring the remaining thyroid lobe and the risk of emerging indications for a second surgery.

Finally, NIFTP does not represent a benign lesion, but rather a ‘low-risk neoplasm’; although the risk of adverse events, including lymph node metastases, is small, it cannot be underestimated. Long-term prospective studies are required to assess the actual prevalence and outcomes of NIFTP.

Declaration of interest

The authors declare that there is no conflict of interest that could be perceived as prejudicing the impartiality of this review.

Funding

The project was financed under the Regional Initiative of Excellence programme of the Minister of Science and Higher Education (project no. 024/RID/2018/19; amount of financing: 11,999,000 zł).

References

- 1 Yu XM, Schneider DF, Levenson G, Chen H & Sippel RS. Follicular variant of papillary thyroid carcinoma is a unique clinical entity: a population-based study of 10,740 cases. *Thyroid* 2013 **23** 1263–1268. (<https://doi.org/10.1089/thy.2012.0453>)
- 2 Rivera M, Ricarte-Filho J, Knauf J, Shaha A, Tuttle M, Fagin JA & Ghossein RA. Molecular genotyping of papillary thyroid carcinoma follicular variant according to its histological subtypes (encapsulated vs infiltrative) reveals distinct BRAF and RAS mutation patterns. *Modern Pathology* 2010 **23** 1191–1200. (<https://doi.org/10.1038/modpathol.2010.112>)
- 3 Liu J, Singh B, Tallini G, Carlson DL, Katabi N, Shaha A, Tuttle RM & Ghossein RA. Follicular variant of papillary thyroid carcinoma: a clinicopathologic study of a problematic entity. *Cancer* 2006 **107** 1255–1264. (<https://doi.org/10.1002/cncr.22138>)
- 4 Nikiforov YE, Seethala RR, Tallini G, Baloch ZW, Basolo F, Thompson LDR, Barletta JA, Wenig BM, Al Ghuzlan A, Kakudo K, *et al.* Nomenclature revision for encapsulated follicular variant of papillary thyroid carcinoma: a paradigm shift to reduce overtreatment of indolent tumors. *JAMA Oncology* 2016 **2** 1023–1029. (<https://doi.org/10.1001/jamaoncol.2016.0386>)
- 5 Haugen BR, Sawka AM, Alexander EK, Bible KC, Caturegli P, Doherty GM, Mandel SJ, Morris JC, Nassar A, Pacini F, *et al.* American Thyroid Association guidelines on the management of thyroid nodules and differentiated thyroid cancer task force review and recommendation on the proposed renaming of encapsulated follicular variant papillary thyroid carcinoma without invasion to noninvasive follicular thyroid neoplasm with papillary-like nuclear features. *Thyroid* 2017 **27** 481–483. (<https://doi.org/10.1089/thy.2016.0628>)
- 6 Baloch ZW, Harrell RM, Brett EM, Randolph G, Garber JR & AACE Endocrine Surgery Scientific Committee and Thyroid Scientific Committee. Managing thyroid tumors diagnosed as non-invasive follicular tumor with papillary like nuclear features (NIFTP). *Endocrine Practice* 2017 [epub]. (<https://doi.org/10.4158/EP171940.DSC>)
- 7 Lloyd RV, Osamura RY, Klöppel G & Rosai J. *WHO Classification of Tumours of Endocrine Organs*, 4th ed. Lyon, France: International Agency for Research on Cancer, 2017.
- 8 Jaconi M, Manzoni M, Pincelli AI, Giardini V, Scardilli M, Smith A, Fellegara G & Pagni F. The impact of the non-invasive follicular thyroid neoplasm with papillary-like nuclear feature terminology in the routine diagnosis of thyroid tumours. *Cytopathology* 2017 **28** 495–502. (<https://doi.org/10.1111/cyt.12459>)

- 9 Kopczyński J, Suligowska A, Niemyska K, Palyga I, Walczyk A, Gašior-Perczak D, Kowalik A, Hińcza K, Mężyk R, Gózdź S, *et al.* The influence of the reclassification of NIFTP as an uncertain tumour on risk of malignancy for the diagnostic categories according to the Bethesda system for reporting thyroid cytopathology. *Endokrynologia Polska* 2019 **70** 232–236. (<https://doi.org/10.5603/EP.a2019.0008>)
- 10 Canberk S, Montezuma D, Taştekin E, Grangeia D, Demirhas MP, Akbas M, Tokat F, Ince U, Soares P & Schmitt F. ‘The other side of the coin’: understanding noninvasive follicular tumor with papillary-like nuclear features in unifocal and multifocal settings. *Human Pathology* 2019 **86** 136–142. (<https://doi.org/10.1016/j.humpath.2018.10.040>)
- 11 Li W, Sciallis A, Lew M, Pang J & Jing X. Implementing noninvasive follicular thyroid neoplasm with papillary-like nuclear features may potentially impact the risk of malignancy for thyroid nodules categorized as AUS/FLUS and FN/SFN. *Diagnostic Cytopathology* 2018 **46** 148–153. (<https://doi.org/10.1002/dc.23866>)
- 12 Mao ML, Joyal T, Picado O, Kerr D, Lew JI & Farrá JC. Noninvasive follicular thyroid neoplasm with papillary-like nuclear features reclassification and its impact on thyroid malignancy rate and treatment. *Journal of Surgical Research* 2018 **230** 47–52. (<https://doi.org/10.1016/j.jss.2018.04.013>)
- 13 Point du Jour K, du Jour KP, Schmitt AC, Chen AY & Griffith CC. Application of strict criteria for noninvasive follicular thyroid neoplasm with papillary-like nuclear features and encapsulated follicular variant papillary thyroid carcinoma: a retrospective study of 50 tumors previously diagnosed as follicular variant PTC. *Endocrine Pathology* 2018 **29** 35–42. (<https://doi.org/10.1007/s12022-017-9509-0>)
- 14 Wong KS, Strickland KC, Angell TE, Nehs MA, Alexander EK, Cibas ES, Krane JF, Howitt BE & Barletta JA. The flip side of NIFTP: an increase in rates of unfavorable histologic parameters in the remainder of papillary thyroid carcinomas. *Endocrine Pathology* 2017 **28** 171–176. (<https://doi.org/10.1007/s12022-017-9476-5>)
- 15 Parente DN, Kluijfhout WP, Bongers PJ, Verzijl R, Devon KM, Rotstein LE, Goldstein DP, Asa SL, Mete O & Pasternak JD. Clinical safety of renaming encapsulated follicular variant of papillary thyroid carcinoma: is NIFTP truly benign? *World Journal of Surgery* 2018 **42** 321–326. (<https://doi.org/10.1007/s00268-017-4182-5>)
- 16 Eskander A, Hall SE, Manduch M, Griffiths R & Irish JC. A population-based study on NIFTP incidence and survival: is NIFTP really a ‘benign’ disease? *Annals of Surgical Oncology* 2019 **26** 1376–1384. (<https://doi.org/10.1245/s10434-019-07187-0>)
- 17 Hirokawa M, Higuchi M, Suzuki A, Hayashi T, Kuma S & Miyauchi A. Noninvasive follicular thyroid neoplasm with papillary-like nuclear features: a single-institutional experience in Japan. *Endocrine Journal* 2017 **64** 1149–1155. (<https://doi.org/10.1507/endocrj.EJ17-0214>)
- 18 Kim TH, Lee M, Kwon AY, Choe JH, Kim JH, Kim JS, Hahn SY, Shin JH, Chung MK, Son YI, *et al.* Molecular genotyping of the non-invasive encapsulated follicular variant of papillary thyroid carcinoma. *Histopathology* 2018 **72** 648–661. (<https://doi.org/10.1111/his.13401>)
- 19 Lee SE, Hwang TS, Choi YL, Kim WY, Han HS, Lim SD, Kim WS, Yoo YB & Kim SK. Molecular profiling of papillary thyroid carcinoma in Korea with a high prevalence of BRAFV600E mutation. *Thyroid* 2017 **27** 802–810. (<https://doi.org/10.1089/thy.2016.0547>)
- 20 Cho U, Mete O, Kim MH, Bae JS & Jung CK. Molecular correlates and rate of lymph node metastasis of non-invasive follicular thyroid neoplasm with papillary-like nuclear features and invasive follicular variant papillary thyroid carcinoma: the impact of rigid criteria to distinguish non-invasive follicular thyroid neoplasm with papillary-like nuclear features. *Modern Pathology* 2017 **30** 810–825. (<https://doi.org/10.1038/modpathol.2017.9>)
- 21 Seo JY, Park JH, Pyo JY, Cha YJ, Jung CK, Song DE, Kwak JJ, Park SY, Na HY, Kim JH, *et al.* A multi-institutional study of prevalence and clinicopathologic features of non-invasive follicular thyroid neoplasm with papillary-like nuclear features (NIFTP) in Korea. *Journal of Pathology and Translational Medicine* 2019 **53** 378–385. (<https://doi.org/10.4132/jptm.2019.09.18>)
- 22 Bychkov A, Jung CK, Liu Z & Kakudo K. Noninvasive follicular thyroid neoplasm with papillary-like nuclear features in Asian practice: perspectives for surgical pathology and cytopathology. *Endocrine Pathology* 2018 **29** 276–288. (<https://doi.org/10.1007/s12022-018-9519-6>)
- 23 Song YS, Lim JA & Park YJ. Mutation profile of well-differentiated thyroid cancer in Asians. *Endocrinology and Metabolism* 2015 **30** 252–262. (<https://doi.org/10.3803/EnM.2015.30.3.252>)
- 24 Hirokawa M, Carney JA, Goellner JR, DeLellis RA, Heffess CS, Katoh R, Tsujimoto M & Kakudo K. Observer variation of encapsulated follicular lesions of the thyroid gland. *American Journal of Surgical Pathology* 2002 **26** 1508–1514. (<https://doi.org/10.1097/0000478-200211000-00014>)
- 25 Kakudo K, Higuchi M, Hirokawa M, Satoh S, Jung CK & Bychkov A. Thyroid FNA cytology in Asian practice-active surveillance for indeterminate thyroid nodules reduces overtreatment of thyroid carcinomas. *Cytopathology* 2017 **28** 455–466. (<https://doi.org/10.1111/cyt.12491>)
- 26 Ruanpeng D, Cheungpasitporn W, Thongprayoon C, Hennessey JV & Shrestha RT. Systematic review and meta-analysis of the impact of noninvasive follicular thyroid neoplasm with papillary-like nuclear features (NIFTP) on cytological diagnosis and thyroid cancer prevalence. *Endocrine Pathology* 2019 **30** 189–200. (<https://doi.org/10.1007/s12022-019-09583-4>)
- 27 Brandt TC, Yee J, Zhou F, Cho M, Cangiarella J, Wei XJ, Yee-Chang M & Sun W. Does noninvasive follicular thyroid neoplasm with papillary-like nuclear features have distinctive features on sonography? *Diagnostic Cytopathology* 2018 **46** 139–147. (<https://doi.org/10.1002/dc.23863>)
- 28 Johnson DN, Furtado LV, Long BC, Zhen CJ, Wurst M, Mujacic I, Kadri S, Segal JP, Antic T & Cipriani NA. Noninvasive follicular thyroid neoplasms with papillary-like nuclear features are genetically and biologically similar to adenomatous nodules and distinct from papillary thyroid carcinomas with extensive follicular growth. *Archives of Pathology and Laboratory Medicine* 2018 **142** 838–850. (<https://doi.org/10.5858/arpa.2017-0118-OA>)
- 29 Kim M, Jeon MJ, Oh HS, Park S, Kim TY, Shong YK, Kim WB, Kim K, Kim WG & Song DE. BRAF and RAS mutational status in noninvasive follicular thyroid neoplasm with papillary-like nuclear features and invasive subtype of encapsulated follicular variant of papillary thyroid carcinoma in Korea. *Thyroid* 2018 **28** 504–510. (<https://doi.org/10.1089/thy.2017.0382>)
- 30 Song YS, Won JK, Yoo SK, Jung KC, Kim MJ, Kim SJ, Cho SW, Lee KE, Yi KH, Seo JS, *et al.* Comprehensive transcriptomic and genomic profiling of subtypes of follicular variant of papillary thyroid carcinoma. *Thyroid* 2018 **28** 1468–1478. (<https://doi.org/10.1089/thy.2018.0198>)
- 31 Giannini R, Ugolini C, Poma AM, Urpi M, Niccoli C, Elisei R, Chiarugi M, Vitti P, Miccoli P & Basolo F. Identification of two distinct molecular subtypes of non-invasive follicular neoplasm with papillary-like nuclear features by digital RNA counting. *Thyroid* 2017 **27** 1267–1276. (<https://doi.org/10.1089/thy.2016.0605>)
- 32 Lastra RR, Birdsong G, Hwang DH, Jorda M, Kerr DA, McGrath C, Odronic S, Rao R, VanderLaan PA, Walker JW, *et al.* Preoperative cytologic interpretation of noninvasive follicular thyroid neoplasm with papillary-like nuclear features: a 1-year multi-institutional experience. *Journal of the American Society of Cytopathology* 2018 **7** 79–85. (<https://doi.org/10.1016/j.jasc.2017.12.004>)
- 33 Zhao L, Dias-Santagata D, Sadow PM & Faquin WC. Cytological, molecular, and clinical features of noninvasive follicular thyroid neoplasm with papillary-like nuclear features versus invasive forms of follicular variant of papillary thyroid carcinoma. *Cancer Cytopathology* 2017 **125** 323–331. (<https://doi.org/10.1002/cncy.21839>)

- 34 Jiang XS, Harrison GP & Datto MB. Young Investigator Challenge: molecular testing in noninvasive follicular thyroid neoplasm with papillary-like nuclear features. *Cancer Cytopathology* 2016 **124** 893–900. (<https://doi.org/10.1002/cncy.21802>)
- 35 Nikiforov YE, Baloch ZW, Hodak SP, Giordano TJ, Lloyd RV, Seethala RR & Wenig BM. Change in diagnostic criteria for noninvasive follicular thyroid neoplasm with papillarylike nuclear features. *JAMA Oncology* 2018 **4** 1125–1126. (<https://doi.org/10.1001/jamaoncol.2018.1446>)
- 36 Seethala RR, Baloch ZW, Barletta JA, Khanafshar E, Mete O, Sadow PM, LiVolsi VA, Nikiforov YE, Tallini G & Thompson LD. Noninvasive follicular thyroid neoplasm with papillary-like nuclear features: a review for pathologists. *Modern Pathology* 2018 **31** 39–55. (<https://doi.org/10.1038/modpathol.2017.130>)
- 37 Oh HS, Kim SJ, Song E, Lee YM, Sung TY, Kim WG, Kim TY & Song DE. Modified transverse-vertical gross examination: a better method for the detection of definite capsular invasion in encapsulated follicular-patterned thyroid neoplasms. *Endocrine Pathology* 2019 **30** 106–112. (<https://doi.org/10.1007/s12022-019-9565-8>)
- 38 Kim MJ, Won JK, Jung KC, Kim JH, Cho SW, Park DJ & Park YJ. Clinical characteristics of subtypes of follicular variant papillary thyroid carcinoma. *Thyroid* 2018 **28** 311–318. (<https://doi.org/10.1089/thy.2016.0671>)
- 39 Ferris RL, Nikiforov Y, Terris D, Seethala RR, Ridge JA, Angelos P, Duh QY, Wong R, Sabra MM, Fagin JA, *et al.* AHSN Series: do you know your guidelines? AHSN Endocrine Section Consensus Statement: state-of-the-art thyroid surgical recommendations in the era of noninvasive follicular thyroid neoplasm with papillary-like nuclear features. *Head and Neck* 2018 **40** 1881–1888. (<https://doi.org/10.1002/hed.25141>)
- 40 Canini V, Leni D, Pincelli AI, Scardilli M, Garancini M, Villa C, Di Bella C, Capitoli G, Cimmini R, Leone BE, *et al.* Clinical-pathological issues in thyroid pathology: study on the routine application of NIFTP diagnostic criteria. *Scientific Reports* 2019 **9** 13179. (<https://doi.org/10.1038/s41598-019-49851-1>)
- 41 Song SJ, LiVolsi VA, Montone K & Baloch Z. Pre-operative features of non-invasive follicular thyroid neoplasms with papillary-like nuclear features: an analysis of their cytological, gene expression classifier and sonographic findings. *Cytopathology* 2017 **28** 488–494. (<https://doi.org/10.1111/cyt.12501>)
- 42 Thompson LD. Ninety-four cases of encapsulated follicular variant of papillary thyroid carcinoma: a name change to noninvasive follicular thyroid neoplasm with papillary-like nuclear features would help prevent overtreatment. *Modern Pathology* 2016 **29** 698–707. (<https://doi.org/10.1038/modpathol.2016.65>)
- 43 Yang GCH & Fried KO. Pathologic basis of the sonographic differences between thyroid cancer and noninvasive follicular thyroid neoplasm with papillary-like nuclear features. *Ultrasonography* 2018 **37** 157–163. (<https://doi.org/10.14366/usg.17045>)
- 44 You SH, Lee KE, Yoo RE, Choi HJ, Jung KC, Won JK, Kang KM, Yoon TJ, Choi SH, Sohn CH, *et al.* Prevention of total thyroidectomy in noninvasive follicular thyroid neoplasm with papillary-like nuclear features (NIFTP) based on combined interpretation of ultrasonographic and cytopathologic results. *Clinical Endocrinology* 2018 **88** 114–122. (<https://doi.org/10.1111/cen.13473>)
- 45 Yang GCH, Fried KO & Scognamiglio T. Sonographic and cytologic differences of NIFTP from infiltrative or invasive encapsulated follicular variant of papillary thyroid carcinoma: a review of 179 cases. *Diagnostic Cytopathology* 2017 **45** 533–541. (<https://doi.org/10.1002/dc.23709>)
- 46 Lam CA, McGettigan MJ, Thompson ZJ, Khazai L, Chung CH, Centeno BA, McIver B & Valderrabano P. Ultrasound characterization for thyroid nodules with indeterminate cytology: inter-observer agreement and impact of combining pattern-based and scoring-based classifications in risk stratification. *Endocrine* 2019 **66** 278–287. (<https://doi.org/10.1007/s12020-019-02000-0>)
- 47 Choi SH, Kim EK, Kwak JY, Kim MJ & Son EJ. Interobserver and intraobserver variations in ultrasound assessment of thyroid nodules. *Thyroid* 2010 **20** 167–172. (<https://doi.org/10.1089/thy.2008.0354>)
- 48 Park SH, Kim SJ, Kim EK, Kim MJ, Son EJ & Kwak JY. Interobserver agreement in assessing the sonographic and elastographic features of malignant thyroid nodules. *American Journal of Roentgenology* 2009 **193** W416–W423. (<https://doi.org/10.2214/AJR.09.2541>)
- 49 Rosario PW. Is Doppler ultrasonography of value for the differentiation between noninvasive follicular thyroid neoplasm with papillary-like nuclear features (NIFTP) and invasive encapsulated follicular variant of papillary thyroid carcinoma? *Clinical Endocrinology* 2018 **88** 506–507. (<https://doi.org/10.1111/cen.13523>)
- 50 Rosario PW, Mourão GF, Nunes MB, Nunes MS & Calsolari MR. Noninvasive follicular thyroid neoplasm with papillary-like nuclear features. *Endocrine-Related Cancer* 2016 **23** 893–897. (<https://doi.org/10.1530/ERC-16-0379>)
- 51 Hahn SY, Shin JH, Oh YL, Kim TH, Lim Y & Choi JS. Role of ultrasound in predicting tumor invasiveness in follicular variant of papillary thyroid carcinoma. *Thyroid* 2017 **27** 1177–1184. (<https://doi.org/10.1089/thy.2016.0677>)
- 52 Rosario PW, da Silva AL, Nunes MB & Borges MAR. Risk of malignancy in thyroid nodules using the American College of Radiology thyroid imaging reporting and data system in the NIFTP era. *Hormone and Metabolic Research* 2018 **50** 735–737. (<https://doi.org/10.1055/a-0743-7326>)
- 53 Rosario PW, Silva TH & de Oliveira PHL. Impact of noninvasive follicular thyroid neoplasm with papillary-like nuclear features (NIFTP) on the risk of malignancy estimated by the ultrasonographic classification of the American Thyroid Association (ATA) in thyroid nodules >1 cm. *Endocrine* 2018 **60** 535–536. (<https://doi.org/10.1007/s12020-018-1585-5>)
- 54 Cibas ES & Ali SZ. The 2017 Bethesda system for reporting thyroid cytopathology. *Thyroid* 2017 **27** 1341–1346. (<https://doi.org/10.1089/thy.2017.0500>)
- 55 Krane JF, Alexander EK, Cibas ES & Barletta JA. Coming to terms with NIFTP: a provisional approach for cytologists. *Cancer Cytopathology* 2016 **124** 767–772. (<https://doi.org/10.1002/cncy.21769>)
- 56 Zhang Z, Chhieng D, Harshan M, Zheng X & Zakowski M. Cytological features of noninvasive follicular thyroid neoplasm with papillary-like nuclear features (NIFTP). *Journal of the American Society of Cytopathology* 2019 **8** 5–10. (<https://doi.org/10.1016/j.jasc.2018.07.007>)
- 57 Brandler TC, Zhou F, Liu CZ, Cho M, Lau RP, Simsir A, Patel KN & Sun W. Can noninvasive follicular thyroid neoplasm with papillary-like nuclear features be distinguished from classic papillary thyroid carcinoma and follicular adenomas by fine-needle aspiration? *Cancer Cytopathology* 2017 **125** 378–388. (<https://doi.org/10.1002/cncy.21848>)
- 58 Maletta F, Massa F, Torregrossa L, Duregon E, Casadei GP, Basolo F, Tallini G, Volante M, Nikiforov YE & Papotti M. Cytological features of ‘noninvasive follicular thyroid neoplasm with papillary-like nuclear features’ and their correlation with tumor histology. *Human Pathology* 2016 **54** 134–142. (<https://doi.org/10.1016/j.humpath.2016.03.014>)
- 59 Bongiovanni M, Giovanella L, Romanelli F & Trimboli P. Cytological diagnoses associated with noninvasive follicular thyroid neoplasms with papillary-like nuclear features according to the Bethesda system for reporting thyroid cytopathology: a systematic review and meta-analysis. *Thyroid* 2019 **29** 222–228. (<https://doi.org/10.1089/thy.2018.0394>)
- 60 Guleria P, Agarwal S, Iyer VK, Jain D, Mathur SR & Yadav D. Subcategorisation of AUS/FLUS thyroid lesions as per the 2017 Bethesda System for Reporting Thyroid Cytopathology:

- a retrospective study from a tertiary care centre analysing risk of malignancy (ROM) of the different subcategories. *Journal of Clinical Pathology* 2019 **72** 771–777. (<https://doi.org/10.1136/jclinpath-2019-205985>)
- 61 Canberk S, Gunes P, Onenerk M, Erkan M, Kilinc E, Kocak Gursan N & Kilicoglu GZ. New concept of the encapsulated follicular variant of papillary thyroid carcinoma and its impact on the Bethesda system for reporting thyroid cytopathology: a single-institute experience. *Acta Cytologica* 2016 **60** 198–204. (<https://doi.org/10.1159/000447990>)
- 62 Faquin WC, Wong LQ, Afrogheh AH, Ali SZ, Bishop JA, Bongiovanni M, Puztaszeri MP, VandenBussche CJ, Gourmaud J, Vaickus LJ, *et al.* Impact of reclassifying noninvasive follicular variant of papillary thyroid carcinoma on the risk of malignancy in the Bethesda System for Reporting Thyroid Cytopathology. *Cancer Cytopathology* 2016 **124** 181–187. (<https://doi.org/10.1002/cncy.21631>)
- 63 Kiernan CM, Weiss VL, Mehrad M, Ely K, Baregamian N & Solórzano CC. New terminology-noninvasive follicular neoplasm with papillary-like nuclear features (NIFTP) and its effect on the rate of malignancy at a single institution. *Surgery* 2018 **163** 55–59. (<https://doi.org/10.1016/j.surg.2017.04.041>)
- 64 Kim M, Kim JE, Kim HJ, Chung YR, Kwak Y & Park SY. Cytologic diagnosis of noninvasive follicular thyroid neoplasm with papillary-like nuclear features and its impact on the risk of malignancy in the Bethesda system for reporting thyroid cytopathology: an institutional experience. *Journal of Pathology and Translational Medicine* 2018 **52** 171–178. (<https://doi.org/10.4132/jptm.2018.04.03>)
- 65 Lau RP, Paulsen JD, Brandler TC, Liu CZ, Simsir A & Zhou F. Impact of the reclassification of ‘noninvasive encapsulated follicular variant of papillary thyroid carcinoma’ to ‘noninvasive follicular thyroid neoplasm With papillary-like nuclear features’ on the Bethesda system for reporting thyroid cytopathology: a large academic institution’s experience. *American Journal of Clinical Pathology* 2017 **149** 50–54. (<https://doi.org/10.1093/ajcp/aqx136>)
- 66 Layfield LJ, Baloch ZW, Esebua M, Kannuswamy R & Schmidt RL. Impact of the reclassification of the non-invasive follicular variant of papillary carcinoma as benign on the malignancy risk of the Bethesda system for reporting thyroid cytopathology: a meta-analysis study. *Acta Cytologica* 2017 **61** 187–193. (<https://doi.org/10.1159/000469654>)
- 67 Lindeman BM, Nehs MA, Angell TE, Alexander EK, Gawande AA, Moore FD, Doherty GM & Cho NL. Effect of noninvasive follicular thyroid neoplasm with papillary-like nuclear features (NIFTP) on malignancy rates in thyroid nodules: how to counsel patients on extent of surgery. *Annals of Surgical Oncology* 2019 **26** 93–97. (<https://doi.org/10.1245/s10434-018-6932-5>)
- 68 Sung S, Margolske E, Chen D & Tiscornia-Wasserman P. Incidence of noninvasive follicular thyroid neoplasm with papillary-like nuclear features and change in risk of malignancy for ‘the Bethesda System for Reporting Thyroid Cytology.’ *Journal of the American Society of Cytopathology* 2019 **8** 133–140. (<https://doi.org/10.1016/j.jasc.2019.01.005>)
- 69 Ventura M, Melo M, Fernandes G & Carrilho F. Risk of malignancy in thyroid cytology: the impact of the reclassification of noninvasive follicular thyroid neoplasm with papillary-like nuclear features (NIFTP). *Endocrine Practice* 2019 **25** 642–647. (<https://doi.org/10.4158/EP-2018-0423>)
- 70 Zhou H, Baloch ZW, Nayar R, Bizzarro T, Fadda G, Adhikari-Guragani D, Hatem J, Larocca LM, Samolczyk J, Slade J, *et al.* Noninvasive follicular thyroid neoplasm with papillary-like nuclear features (NIFTP): implications for the risk of malignancy (ROM) in the Bethesda System for Reporting Thyroid Cytopathology (TBSRTC). *Cancer Cytopathology* 2018 **126** 20–26. (<https://doi.org/10.1002/cncy.21926>)
- 71 Vuong HG, Tran TTK, Bychkov A, Jung CK, Nakazawa T, Kakudo K, Katoh R & Kondo T. Clinical impact of non-invasive follicular thyroid neoplasm with papillary-like nuclear features on the risk of malignancy in the Bethesda system for reporting thyroid cytopathology: a meta-analysis of 14,153 resected thyroid nodules. *Endocrine Practice* 2019 **25** 491–502. (<https://doi.org/10.4158/EP-2018-0506>)
- 72 Bychkov A, Keelawat S, Agarwal S, Jain D, Jung CK, Hong S, Lai CR, Satoh S & Kakudo K. Impact of non-invasive follicular thyroid neoplasm with papillary-like nuclear features on the Bethesda system for reporting thyroid cytopathology: a multi-institutional study in five Asian countries. *Pathology* 2018 **50** 411–417. (<https://doi.org/10.1016/j.pathol.2017.11.088>)
- 73 Bongiovanni M, Faquin WC, Giovanella L, Durante C, Kopp P & Trimboli P. Impact of non-invasive follicular thyroid neoplasms with papillary-like nuclear features (NIFTP) on risk of malignancy in patients undergoing lobectomy/thyroidectomy for suspicious for malignancy or malignant fine-needle aspiration cytology findings: a systematic review and meta-analysis. *European Journal of Endocrinology* 2019 **181** 389–396. (<https://doi.org/10.1530/EJE-19-0223>)
- 74 Strickland KC, Vivero M, Jo VY, Lowe AC, Hollowell M, Qian X, Wieczorek TJ, French CA, Teot LA, Sadow PM, *et al.* Preoperative cytologic diagnosis of noninvasive follicular thyroid neoplasm with papillary-like nuclear features: a prospective analysis. *Thyroid* 2016 **26** 1466–1471. (<https://doi.org/10.1089/thy.2016.0280>)
- 75 Legesse T, Parker L, Heath J & Staats PN. Distinguishing non-invasive follicular thyroid neoplasm with papillary-like nuclear features (NIFTP) from classic and invasive follicular-variant papillary thyroid carcinomas based on cytologic features. *Journal of the American Society of Cytopathology* 2019 **8** 11–17. (<https://doi.org/10.1016/j.jasc.2018.07.004>)
- 76 Koshikawa T, Fujita N, Ueda N, Ota Y, Sasaki E, Murakami Y, Hosoda W, Yatabe Y, Hanai N, Higuchi M, *et al.* Important cytological findings for distinction between follicular variant and conventional papillary thyroid carcinoma, including noninvasive follicular thyroid tumors with papillary-like nuclear features. *Endocrine Journal* 2019 **66** 475–483. (<https://doi.org/10.1507/endocrj.EJ18-0525>)
- 77 Strickland KC, Eszlinger M, Paschke R, Angell TE, Alexander EK, Marqusee E, Nehs MA, Jo VY, Lowe A, Vivero M, *et al.* Molecular testing of nodules with a suspicious or malignant cytologic diagnosis in the setting of non-invasive follicular thyroid neoplasm with papillary-like nuclear features (NIFTP). *Endocrine Pathology* 2018 **29** 68–74. (<https://doi.org/10.1007/s12022-018-9515-x>)
- 78 Bizzarro T, Martini M, Capodimonti S, Straccia P, Lombardi CP, Pontecorvi A, Larocca LM & Rossi ED. Young investigator challenge: the morphologic analysis of noninvasive follicular thyroid neoplasm with papillary-like nuclear features on liquid-based cytology: some insights into their identification. *Cancer Cytopathology* 2016 **124** 699–710. (<https://doi.org/10.1002/cncy.21777>)
- 79 Strickland KC, Howitt BE, Barletta JA, Cibas ES & Krane JF. Suggesting the cytologic diagnosis of noninvasive follicular thyroid neoplasm with papillary-like nuclear features (NIFTP): a retrospective analysis of atypical and suspicious nodules. *Cancer Cytopathology* 2018 **126** 86–93. (<https://doi.org/10.1002/cncy.21922>)
- 80 Kwon H, Jeon MJ, Yoon JH, Hong SJ, Lee JH, Kim TY, Shong YK, Kim WB, Kim WG & Song DE. Preoperative clinicopathological characteristics of patients with solitary encapsulated follicular variants of papillary thyroid carcinomas. *Journal of Surgical Oncology* 2017 **116** 746–755. (<https://doi.org/10.1002/jso.24700>)
- 81 Kwon MR, Shin JH, Hahn SY, Oh YL, Kwak JY, Lee E & Lim Y. Histogram analysis of greyscale sonograms to differentiate between the subtypes of follicular variant of papillary thyroid cancer. *Clinical Radiology* 2018 **73** 591.e1–591.e7. (<https://doi.org/10.1016/j.crad.2017.12.008>)
- 82 Hahn SY, Shin JH, Lim HK, Jung SL, Oh YL, Choi IH & Jung CK. Preoperative differentiation between noninvasive follicular

- thyroid neoplasm with papillary-like nuclear features (NIFTP) and non-NIFTP. *Clinical Endocrinology* 2017 **86** 444–450. (<https://doi.org/10.1111/cen.13263>)
- 83 Lee HS, Lee JW, Park JH, Kim WS, Han HS & Lee SE. Comprehensive analysis for diagnosis of preoperative non-invasive follicular thyroid neoplasm with papillary-like nuclear features. *PLoS ONE* 2019 **14** e0218046. (<https://doi.org/10.1371/journal.pone.0218046>)
- 84 Díaz Del Arco C & Fernández Aceñero MJ. Noninvasive follicular thyroid neoplasm with papillary-like nuclear features: can cytology face the challenge of diagnosis in the light of the new classification? *Acta Cytologica* 2018 **62** 265–272. (<https://doi.org/10.1159/000488579>)
- 85 Sohn SY, Lee JJ & Lee JH. Molecular profile and clinicopathologic features of follicular variant papillary thyroid carcinoma. *Pathology Oncology Research* 2019 [epub]. (<https://doi.org/10.1007/s12253-019-00639-8>)
- 86 Xu B, Tuttle RM, Sabra MM, Ganly I & Ghossein R. Primary thyroid carcinoma with low-risk histology and distant metastases: clinicopathologic and molecular characteristics. *Thyroid* 2017 **27** 632–640. (<https://doi.org/10.1089/thy.2016.0582>)
- 87 Proietti A, Sartori C, Macerola E, Borrelli N, Materazzi G, Vitti P & Basolo F. Low frequency of tert promoter mutations in a series of well-differentiated follicular-patterned thyroid neoplasms. *Virchows Archiv* 2017 **471** 769–773. (<https://doi.org/10.1007/s00428-017-2236-6>)
- 88 Jug RC, Datto MB & Jiang XS. Molecular testing for indeterminate thyroid nodules: performance of the Afirma gene expression classifier and ThyroSeq panel. *Cancer Cytopathology* 2018 **126** 471–480. (<https://doi.org/10.1002/cncy.21993>)
- 89 Steward DL, Carty SE, Sippel RS, Yang SP, Sosa JA, Sipos JA, Figge JJ, Mandel S, Haugen BR, Burman KD, *et al.* Performance of a multigene genomic classifier in thyroid nodules with indeterminate cytology: a prospective blinded multicenter study. *JAMA Oncology* 2019 **5** 204–212. (<https://doi.org/10.1001/jamaoncol.2018.4616>)
- 90 Valderrabano P, Khazai L, Leon ME, Thompson ZJ, Ma Z, Chung CH, Hallanger-Johnson JE, Otto KJ, Rogers KD, Centeno BA, *et al.* Evaluation of ThyroSeq v2 performance in thyroid nodules with indeterminate cytology. *Endocrine-Related Cancer* 2017 **24** 127–136. (<https://doi.org/10.1530/ERC-16-0512>)
- 91 Sowder AM, Witt BL & Hunt JP. An update on the risk of lymph node metastasis for the follicular variant of papillary thyroid carcinoma with the new diagnostic paradigm. *Head and Neck Pathology* 2018 **12** 105–109. (<https://doi.org/10.1007/s12105-017-0835-9>)
- 92 Paniza ACJ, Mendes TB, Vianna MDB, Thomaz DMD, Chiappini PBO, Colazza-Gama GA, Lindsey SC, de Carvalho MB, Alves VAF, Curione O, *et al.* Revised criteria for diagnosis of NIFTP reveals a better correlation with tumor biological behavior. *Endocrine Connections* 2019 **8** 1529–1538. (<https://doi.org/10.1530/EC-19-0459>)
- 93 Xu B, Tallini G, Scognamiglio T, Roman BR, Tuttle RM & Ghossein RA. Outcome of large noninvasive follicular thyroid neoplasm with papillary-like nuclear features. *Thyroid* 2017 **27** 512–517. (<https://doi.org/10.1089/thy.2016.0649>)
- 94 Rosario PW. Long-term outcomes of patients with noninvasive follicular thyroid neoplasm with papillary-like nuclear features (NIFTP) ≥ 4 cm treated without radioactive iodine. *Endocrine Pathology* 2017 **28** 367–368. (<https://doi.org/10.1007/s12022-017-9493-4>)
- 95 Shafiq K, LiVolsi VA, Montone K & Baloch ZW. Papillary thyroid microcarcinoma: reclassification to non-invasive follicular thyroid neoplasm with papillary-like nuclear features (NIFTP): a retrospective clinicopathologic study. *Endocrine Pathology* 2018 **29** 339–345. (<https://doi.org/10.1007/s12022-018-9546-3>)
- 96 Xu B, Farhat N, Barletta JA, Hung YP, de Biase D, Casadei GP, Onenerk AM, Tuttle RM, Roman BR, Katabi N, *et al.* Should subcentimeter non-invasive encapsulated, follicular variant of papillary thyroid carcinoma be included in the noninvasive follicular thyroid neoplasm with papillary-like nuclear features category? *Endocrine* 2018 **59** 143–150. (<https://doi.org/10.1007/s12020-017-1484-1>)
- 97 Rosario PW, Mourão GF, Oliveira LFF & Calsolari MR. Long-term follow-up in patients with noninvasive follicular thyroid neoplasm with papillary-like nuclear features (NIFTP) without a suspicion of persistent disease in postoperative assessment. *Hormone and Metabolic Research* 2018 **50** 223–226. (<https://doi.org/10.1055/s-0043-121707>)

Received in final form 2 February 2020

Accepted 12 February 2020

Accepted Manuscript published online 12 February 2020